J. Cosmet. Sci., **50**, 159–170 (May/June 1999)

Histopathological, morphometric, and stereologic studies of dermocosmetic skin formulations containing vitamin A and/or glycolic acid

PATRICIA MARIA BERARDO GONÇALVES MAIA CAMPOS,
GISLAINE RICCI, MARISA SEMPRINI, and
RUBERVAL A. LOPES, *Faculty of Pharmaceutical Sciences of Ribeirão Preto (P.M.B.G.M.C., G.R.) and Dental School of Ribeirão Preto (M.S., R.A.L.), University of São Paulo, São Paulo, Brazil.*

Accepted for publication April 30, 1999.

Synopsis

Among the many active agents for dermocosmetic purposes that have been described, marketed, and prescribed, vitamins (vitamin A palmitate among them) and alpha-hydroxy acids such as glycolic acid have been gaining scientific importance. Vitamin A palmitate contributes to the maintenance of skin softness and smoothness, improving the water barrier properties of the tissue. Glycolic acid has yielded highly satisfactory results in terms of recovery of aged skin. The combination of low concentrations of glycolic acid with vitamin A palmitate has been extensively used in dermocosmetic formulations. The objective of the present study was to investigate the histopathological alterations caused by formulations containing vitamin A and/or glycolic acid in guinea pig skin, determined by appropriate stereologic techniques.

The following formulations were applied to specific shaved areas of guinea pig skin: gel alone (used as the dermocosmetic base), gel with vitamin A added, gel with glycolic acid added, and gel with both vitamin A and glycolic acid added. After application of the formulations for one week, skin biopsies were obtained from the animals and we investigated the histopathological alterations.

Under the present experimental conditions, both the formulations containing vitamin A and glycolic acid caused increased epidermal thickness, with cells of larger volume due to intra- and extracellular edema (hydration). This epithelial thickening was not limited to the upper cell layers but was also present in the basal and spinous layers. These alterations were even more evident with the use of the formulation containing a combination of vitamin A and glycolic acid.

INTRODUCTION

Among the countless active principles used for dermocosmetic purposes, vitamins (and vitamin A palmitate among them) and alpha-hydroxy acids (such as glycolic acid) have gained notoriety due to their pharmacodynamic properties (1). Alpha-hydroxy acids, a group of natural substances found in fruits and in other foods, have been widely used by the cosmetics industry for the preparation of anti-aging skin formulations.

Vitamin A palmitate acts on the skin by keeping it in good condition and favoring its correct metabolism. It acts on epithelization in dry and rough skin, as well as on keratinization considered to be abnormal. Vitamin A palmitate has been used in dermocosmetic preparations in combination with glycolic acid because the latter reduces the cohesion of corneocytes, stimulating skin desquamation, which in turn facilitates vitamin A absorption by the skin and leads to the expected results.

Alpha-hydroxy acids are being incorporated into a new generation of treatment cosmetics. This is a new and interesting chapter in the formulation and scientific investigation of these products, since satisfactory results in the recovery of aged skin can be obtained with much simpler molecules.

The objective of the present study was to investigate the histopathological alterations caused by dermocosmetic formulations containing vitamin A and/or glycolic acid in guinea pig skin, determined by appropriate stereologic techniques.

EXPERIMENTAL PROCEDURE

FORMULATIONS STUDIED

We used a non-ionic gel formulation consisting of 2% hydroxy-ethyl-cellulose, 2% glycerin, 3% propyleneglycol, 0.2% methyldibromo-glutaronitrile and phenoxyethanol, 0.01% alpha-tocopherol and distilled water, with and without the addition of 0.5% vitamin A palmitate (1,000,000 IU/g) and/or 4.2% glycolic acid.

BIOLOGICAL ASSAY

Animals. Adult guinea pigs weighing on average 350 g were used. The animals were kept in individual cages and received commercial ration and green food (rami), as well as water *ad libitum.*

Treatment. Five areas measuring 1 cm in diameter were shaved on each side of the dorsum of each animal, one of them used as control and the other four for the application of the cosmetic formulations. The formulations were applied daily for one week. The treatment was as follows: a) area I, no treatment (control); b) area II, application of the gel only; c) area III, application of the gel with vitamin A added; d) area IV, application of the gel with glycolic acid added; e) area V, application of the gel with vitamin A and glycolic acid added.

Histology. After one week of treatment the guinea pigs were sacrificed and skin fragments were obtained from each shaved area and immediately immersed in a fixing solution of 85 ml of 80% alcohol, 10 ml formalin, and 5 ml acetic acid. The fragments were fixed for 24 hours and then dehydrated, cleared, and embedded in paraffin. Serial 6-μm-thick sections were then obtained, and ten sections per block were obtained from a total of 500 sections, so that each of these ten sections would correspond to an interval of 50 sections. The sections were stained with hematoxylin and eosin.

Morphometry and karyometry. For the morphometric study (analysis of the nucleus of the epithelial layers), the skin sections obtained from each experimental group were analyzed with a Henamed light microscope equipped with a 100× immersion objective and a light camera (Jena).

The largest and smallest diameters of the nuclei of the basal and spinous layers of the epidermis were measured in drawings of the image projected onto paper at a final magnification of 1000×. The nuclear images obtained were traced with a no. 2 black pencil, with care taken to consider only elliptical images. The largest and smallest axes of these images were then measured with the aid of draft paper. The following karyometric parameters were estimated:

- Mean diameter: $M = (D \cdot d)^{1/2}$
- Perimeter: $P = (\pi/2) \cdot [1.5 \cdot (D + d) - M]$
- Largest diameter/smallest diameter ratio: D/d
- Volume: $V = 6^{-1} \cdot \pi \cdot M^3$
- Area: $A = \pi \cdot M^{2/4}$
- Area/volume ratio: $3/2 \cdot M$
- Shape coefficient: $F = 4 \cdot \pi \cdot A/p2$
- Contour index: $I = P/(A)^{1/2} \cdot (D - d)^{1/2}/D$

Stereology. In the present study we used a grid, idealized by Merz (2), printed on paper to draw the epithelial structures. The grid consists of a square that limits the test area, containing a system of points marked on a sinuous line formed by the succession of enchained semicircles. The Merz grid can be used to count points on a given histological structure, and also to count intersections between two contiguous structures, by considering the number of points that fall on the structure under study in the former case and the number of times that neighboring surfaces cut the curved line in the latter.

Thus, in order to obtain the nucleus-cytoplasm ratio, the thickness, the numerical nuclear density, the epithelial volume/interface ratio, the cytoplasmic volume, and the epithelial volume, we used point counting (2000 per animal, corresponding to the product of 20 microscope fields per 100 points on the grid) or the number of intersections, according to the requirements of the stereologic equation with respect to the parameter studied.

Nucleus/cytoplasm (n/c) ratio. The nucleus/cytoplasm ratio is given by the ratio of the relative volumes of nucleus and cytoplasm:

$$n/c = \frac{Vvn}{Vvcyt}$$

The relative volumes are determined by the number of points falling on the structure considered (3–5). The value thus obtained is an overestimate of the real value due to the so-called "Holmes effect" (5), which results from the use of histological sections of finite thickness. To correct this overestimate it is necessary to take into account the size of the structure involved and the thickness of the histological section. Henning (6) proposed the following corrective formula for the Holmes effect, in which the nuclei are seen as if they were spheres of mean diameter D, and T is the thickness of the section:

$$Vvc = \frac{Vvn}{1 + 3T/2D}$$

In this expression Vvc is the corrected volumetric fraction of the nuclei, and Vvn is the observed volumetric fraction calculated by dividing the number of points falling on the nuclei by the total number of points falling on the nucleus and cytoplasm. The mean

diameter (D) is the same as previously determined by karyometry. The corrected nucleus/cytoplasm ratio will then be:

$$\text{Corrected n/c} = \frac{\text{Vvc}}{1 - \text{Vvc}}$$

where 1 - Vvc is the corrected volumetric cytoplasmic fraction (Vvcyt).

Numerical nuclear density (Nvn). The area of the epithelium within the test system was evaluated by counting the points that fall on it, and the epithelial volume was proportional to it. The nuclei inside the standard square were then counted. The total area of the square was 50.625 μm^2 in two fields per section, for a total of 20 fields per block, and this permitted us to obtain the number of nuclear sections of the area (Nav). The number of nuclei per unit volume (numerical nuclear density, Nvn) was calculated using the Abercrombie (7) correlation modified by Elias *et al.* (8):

$$\text{Nvn} = \frac{\text{Nav}}{\text{D} + \text{T}}$$

where D is the mean nuclear diameter previously estimated by karyometry, and t is the thickness of the section (6 μm). The result obtained corresponds to the number of nuclei per mm^3.

External surface/basal layer (V/S) ratio. To determine this ratio we counted the number of times the test line intersected the interface under study (keratin or connective tissue). The V/S ratio is given by the equation:

$$\text{V/S} = \frac{\text{P} \cdot \text{I}}{4\text{I}}$$

where P is the number of points that fall on the epithelium, I the number of intersections of the test line with the interface under study, and I the length of the test line, determined by the ratio:

$$\text{I} = \frac{\text{d} \cdot 1}{2}$$

where d is the distance between two contiguous points marked on the test line.

The fact that the epithelial volume (Vep) is constant for each field permits the establishment of a direct relation between the surface areas of the two interfaces corresponding to the same standard volume:

$$\frac{\text{IK/Vep}}{\text{Ict/Vep}} = \frac{\text{IK}}{\text{Ict}}$$

where IK and Ict are the numbers of intersections of the test line with the epithelium–keratin and epithelium–connective tissue intersections. The V/S ratio was inverted to obtain the IK/Ict ratio instead of the Ict/IK ratio.

Cytoplasmic volume and epithelial cell volume. Cytoplasmic volume (Vct) was estimated from the previously determined nuclear volume and the corrected nucleus/cytoplasm ratio. In turn, the sum of the mean nuclear and cytoplasmic volumes provides the estimated value of the epithelial cell. The cytoplasmic volume is given by the ratio:

$$Vct = \frac{Vn}{\text{corrected n/c}}$$

The volume of the epithelial cell, in turn, is given by the equation:

$$V\ cel = Vn + Vct$$

Mean epithelial thickness. Mean epithelial thickness was estimated by the formula of Weibel (9):

$$E = \frac{P \cdot L}{2(IK + Ict)}$$

where P is the number of points that fell on the epithelium, L is the length of the test line, and IK and Ict are the numbers of intersections of the test line with the epithelium–keratin interface and the epithelium–connective tissue interface, respectively.

Statistical analysis. Data were analyzed statistically using nonparametric tests such as the Mann-Whitney and median tests. Data analysis and the mathematical calculations involved in the stereologic studies were performed using several programs elaborated in the Department of Stomatology, Dental School of Ribeirão Preto, USP, by Profs. Geraldo Maia Campos and Miguel Angel Sala Di Matteo using ADVANCED BASIC language.

RESULTS AND DISCUSSION

HISTOPATHOLOGY

Group I (control). The lining epithelium of the guinea pig epidermis is of the keratinized stratified pavement type (Figure 1). The basal layer is clearly visible, resting on the basement membrane and consisting of low cells with scarce cytoplasm and an ovoid nucleus slightly more stained than the nuclei of more superficial layers. The cells of this layer are well organized and arranged in such a way that the long axis is perpendicular to the basement membrane. The spinous layer, located above the basal layer, consists of more voluminous cells with nuclei containing sparse chromatin and clearly visible nucleoli. These cells tend to be arranged in such a way that the long axis is parallel to the surface. Above this layer is the granulose layer, whose cells contain keratin-hyaline granules in the cytoplasm. The horny layer is located in the outermost portion and consists of keratin filaments firmly adhering to the granulose layer. The dermis, located immediately below the epidermis, consists of a layer of connective tissue.

Group II (gel only). In this group the epidermis was thicker, with barely developed papillae. The cells of the basal and spinous layers were more voluminous and the nuclei of weak chromatin were also more voluminous. Some of these cells were edematous. The granulose layer was clearly visible and the horny layer was thinner (Figure 2).

Group III (gel + vitamin A). In this group, the aspect of the epidermis was quite similar to that observed in Group II. The cells of the basal and spinous layers, as well as their nuclei, were more voluminous. The thickness of the epithelium was more evident, and the basal and spinous layers were also thicker. The granulose layer presented cells filled

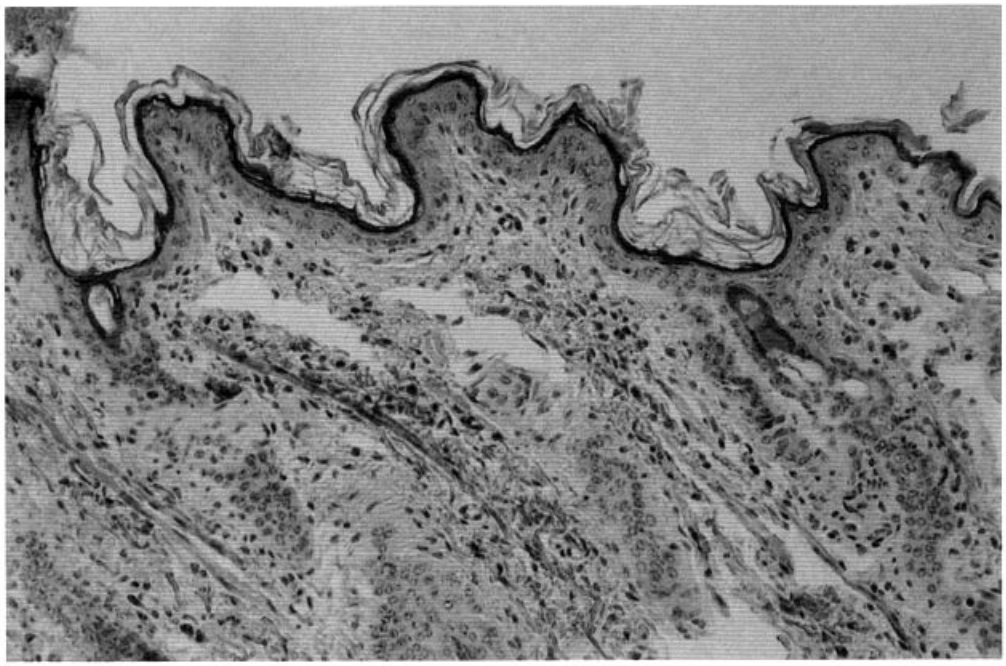

Figure 1. Guinea pig epidermis. Group I (control).

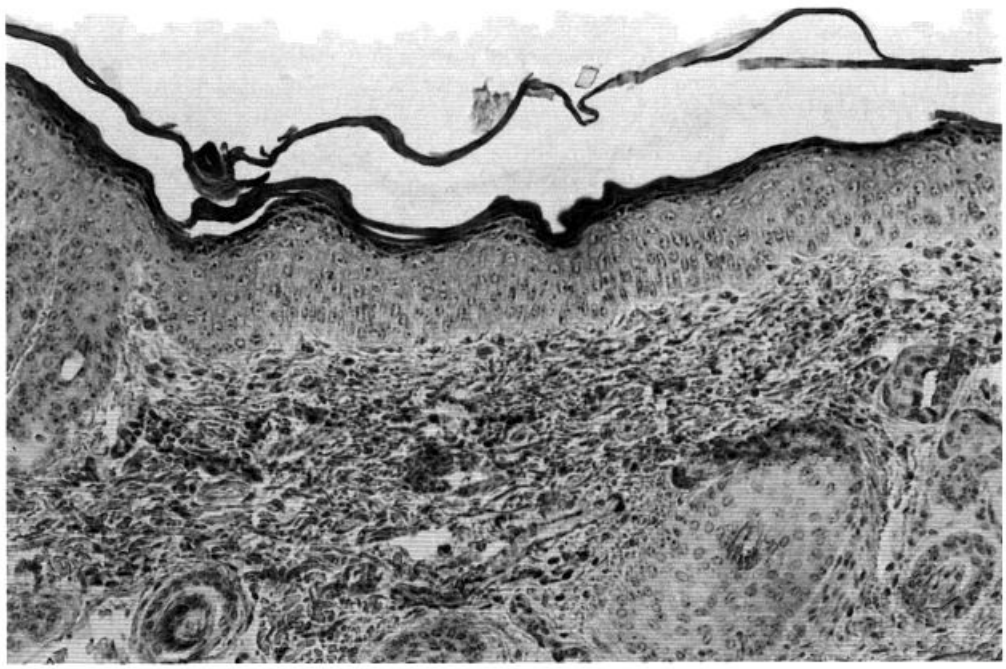

Figure 2. Guinea pig epidermis. Group II (gel only).

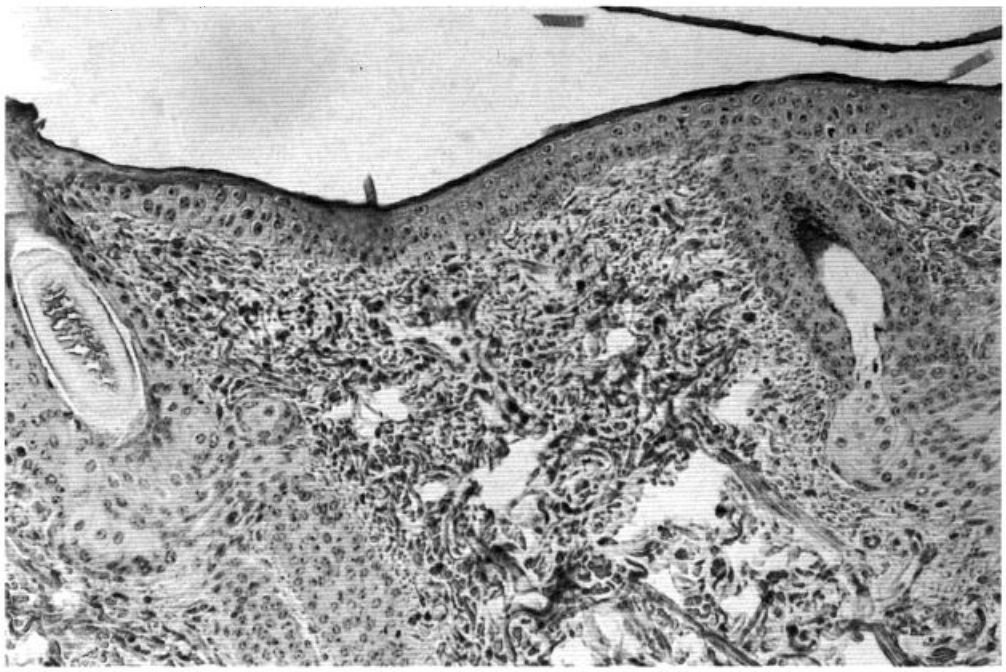

Figure 3. Guinea pig epidermis. Group III (gel + vitamin A).

with basophilic granules. The horny layer was less thick, and some spinous cells were edematous (Figure 3).

Group IV (gel + glycolic acid). The thickness of the epidermis was greatly increased, with larger cells and nuclei of various volumes. The basal and spinous layers also showed increased thickness. The granulosa was thicker, with cells containing rough granules of different sizes. The horny layer was thinner and still retained some nuclei. The limits of the spinous cells were clearly visible, and some of these cells were edematous. The presence of spacing between cells was also evident, possibly due to edema (Figure 4).

Group V (gel + vitamin A + glycolic acid). This combination caused a greater thickness of the epidermis than observed in the previous groups. The cells reached the largest volume, and the nuclei, containing clear chromatin, were also more voluminous. The signs of edema were much more visible, both inside and outside the cells. The granulose layer was thicker, and the keratin-hyaline granules were rough, of increased size, and showed signs of fusion. The horny layer was thinner and detached (Figure 5).

MORPHOMETRIC RESULTS (KARYOMETRY)

The nuclei of the basal layer, when evaluated morphometrically, were greatly increased in the areas treated with the formulations tested, with significantly larger volume, area, and perimeter (Table I). The shape of the cells was unchanged in areas II, III, and IV. As observed histopathologically, the nuclei of the cells of the spinous layer presented significantly increased volume, area, and perimeter, with no changes in shape (Table II).

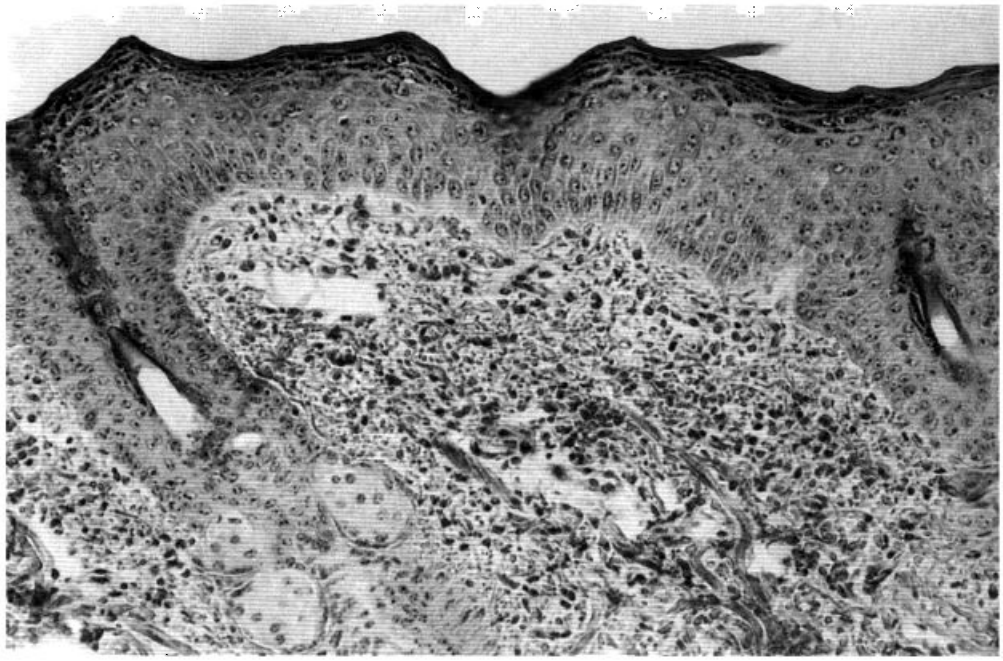

Figure 4. Guinea pig epidermis. Group IV (gel + glycolic acid).

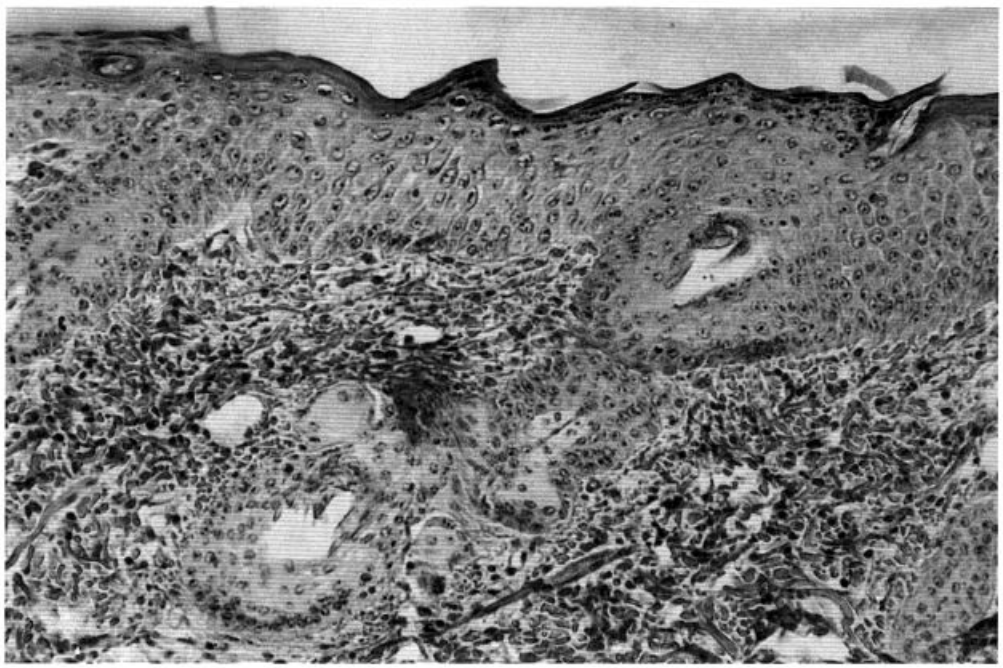

Figure 5. Guinea pig epidermis. Group V (gel + vitamin A + glycolic acid).

Table I
Mean Karyometric Values of Cells of the Basal Epidermal Layer of Control Guinea Pigs and of Guinea Pigs Topically Treated With Cosmetic Preparations (Mann-Whitney test)

Parameter	Groups				
	Control	T_{II}	T_{III}	T_{IV}	T_V
Larger diameter (μm)	6.88	9.18*	7.82**	8.68*	8.38*
Smaller diameter (μm)	4.79	5.96*	5.52*	5.84*	5.28*
Mean geometric diameter (μm)	5.72	7.37*	6.55*	7.09*	6.62*
D/d ratio	1.46	1.57*	1.43^{ns}	1.51^{ns}	1.61*
Volume (μm^3)	101.88	215.71*	151.13*	192.74*	155.83*
Area (μm^2)	26.03	43.08*	33.99*	39.91*	34.74*
V/A ratio	3.81	4.91*	4.36*	4.73*	4.42*
Perimeter (μm)	18.50	24.09*	21.13*	23.06*	21.79*
Eccentricity	0.70	0.74^{ns}	0.69^{ns}	0.71^{ns}	0.75*
Form coefficient	0.94	0.93^{ns}	0.95^{ns}	0.94^{ns}	0.92*
Outline index	3.65	3.69**	3.64^{ns}	3.67^{ns}	3.71*

* $p < 0.01$; ** $p < 0.05$; ns, Nonsignificant.

Table II
Mean Karyometric Values of the Spinous Layer Cells of the Epidermis of Control Guinea Pigs and of Guinea Pigs Topically Treated With Cosmetic Preparations (Mann-Whitney test)

Parameter	Groups				
	Control	T_{II}	T_{III}	T_{IV}	T_V
Larger diameter (μm)	6.78	9.18*	7.94**	8.23*	7.21*
Smaller diameter (μm)	4.50	6.10*	5.50*	5.87*	5.68*
Mean geometric diameter (μm)	5.55	7.46*	6.59*	6.93*	6.68*
D/d ratio	1.51	1.53^{ns}	1.46^{ns}	1.42**	1.41**
Volume (μm^3)	90.95	222.62*	153.13*	178.93*	161.52*
Area (μm^2)	24.33	44.05*	34.35*	38.05*	34.46*
V/A ratio	3.69	4.97*	4.39*	4.62*	4.45*
Perimeter (μm)	17.81	24.31*	21.333*	22.34*	21.54*
Eccentricity	0.73	0.72^{ns}	0.69**	0.67*	0.66*
Form coefficient	0.96	0.94^{ns}	0.95^{ns}	0.95^{ns}	0.95^{ns}
Outline index	3.63	3.68^{ns}	3.65^{ns}	3.64^{ns}	3.64^{ns}

* $p < 0.01$; ** $p < 0.05$; ns, Nonsignificant.

STEREOLOGIC RESULTS

The basal layer was stereologically thicker in the areas treated with the formulations, and this was more evident in the presence of glycolic acid. Although thicker, the basal layer presented a smaller number of cells. This increase was compared on the basis of increased cytoplasmic and cellular volumes (Table III). The same was observed with respect to the spinous layer (Table III).

When the epidermis was considered as a whole, there was increased thickening, especially after the use of glycolic acid. This increased thickening was also reflected on the decreased surface density. The number of cells per mm^3 was decreased (Table III). The horny layer was not evaluated quantitatively because of the trauma cased by shaving.

Table III
Mean Values of the Stereologic Parameters of Epidermal Cells of Control Guinea Pigs and of Guinea Pigs Topically Treated With Cosmetic Preparations (Mann-Whitney test)

Parameter	Groups				
	Control	T_{II}	T_{III}	T_{IV}	T_V
Germinative layer					
Cytoplasm volume (m^3)	620.33	1010.08*	1016.69*	764.14**	1323.44*
Cell volume	718.94	1220.32*	1164.57*	951.41*	1476.18*
N/C ratio	0.16	0.21*	0.15^{ns}	0.25*	0.12**
Thickness (μm^3)	7.32	11.51*	11.11*	16.56*	16.26*
Numerical density (n^0/mm^3)	1438348	825519*	869289*	1059321*	712823*
Spinous layer					
Cytoplasm volume (μm^3)	1067.43	1901.33*	2144.54*	1473.18*	2552.61*
Cell volume (μm^3)	1157.09	2119.41*	2294.59*	1648.15*	2709.33*
N/C ratio	0.08	0.11*	0.07^{ns}	0.14^{ns}	0.06*
Thickness (μm^3)	9.36	16.95*	23.71*	29.43*	37.78*
Numerical density (n^0/mm^3)	876950	476206*	471392*	665843*	374095*
Total thickness					
Surface density (mm^2/mm^3)	4.76	2.58*	2.38*	1.52*	1.40*
Thickness (μm^3)	22.72	34.98**	39.90**	59.59	64.57*
Outer layer/basal layer ratio	1.04	1.04^{ns}	1.01^{ns}	1.00^{ns}	1.00^{ns}
Numerical density (n^0/mm^3)	1011357	487789*	526503*	620644*	401681*

* $p < 0.01$; **$p < 0.05$; ns, Nonsignificant.

MECHANISMS OF ACTION OF ALPHA-HYDROXY ACIDS (AHAs)

AHAs are widely used in therapy since they have specific effects on the skin structures. When applied to the skin in high concentrations, AHAs cause the release of keratinocytes and epidermolysis, and when applied at low concentrations they reduce the cohesion between corneocytes and cause evident desquamation of the horny layer. AHAs are involved in many metabolic processes: they participate in essential cellular mechanisms such as the Krebs cycle, glycolysis, and serine biosynthesis. Furthermore, they promote collagen maturation and glycosaminoglycan formation (10,11).

The reduction in corneocyte cohesion caused by the action of AHAs occurs at lower levels in the horny layer, and this fact involves a dynamic and active process in a particular step of keratinization. Among the various possibilities, there may be a modification of ion binding or the dissolution of desmosomes due to the reduced pH (11).

According to Van Scott and Yu (12), AHAs reduce the cohesion of corneocytes by affecting ion bonds, as follows: 1) by hydration of the horny layer, increasing the distance between corneocytes and consequently reducing cellular cohesion. In our material glycolic acid provoked a deep hydration not only in the horny layer, but also in the spinous one, resulting in greatly thickened epithelium and wide separation between cells; 2) by

reduction of electron-negative sulfate and phosphate groups of the outer wall of the corneocytes due to the enzymatic inhibition of transferases and kinases, a fact that would provoke the loss of cohesive strength.

The hydration effect obtained in our experiments is very important when the cosmetic products containing glycolic acid are used, because there is a great interest in the research of the active substance with hydration properties.

The moisturizing products are some of the most important types of cosmetics, because these act to prevent atopic xeroxis and cutaneous early aging and are used to support the treatment of several alterations. There are several moisturizing agents used in cosmetic products—for example, aminoacids, urea, latic acid, silicones, vegetable and mineral oils, liposomes, polymers, and ceramides, which act by different mechanisms, such as occlusive mechanism or carrying water into the skin surface (13,14).

In our paper, the glycolic acid and vitamin A provoked the hydration effect by intra- and extracellular edema. This effect is very interesting and beneficial because it can improve cutaneous hydration, and it is not limited to the upper cells layers but is also present in the deeper ones.

AHAs provoke a reduction in pH even in the deep layers of the horny layer (11), and the reduced pH contributes to desmosome dissolution. A reduced pH provokes maximum activity of certain enzymes, resulting in increased cell proliferation and differentiation. AHAs also stimulate epidermal proliferation by acting on keratinocytes. The changes observed in normal skin treated with AHAs (15) are similar to those observed in wound cicatrization (16) during the period of reaction after steroid-induced atrophy (17) and in treatment of the skin with retinoic acid (18). Increased total epidermal thickness, as well as increased numbers of granular layers, suggest that AHAs may stimulate changes in the epidermis.

In the present study, glycolic acid stimulated an increase in the thickness of the granulose layer in the guinea pig skin, with cells filled with rough and fused keratin-hyalin granules. The epidermal thickening observed was due to the intra- and extracellular hydration (beneficial edema, in this case) and the nuclear volume increase. In the basal layer it may be suggested that the increase in nuclear activity occurred in the group treated with the formulation containing glycolic acid and vitamin A palmitate, due to alterations observed in the eccentricity, form coefficient e outline index ($p < 0.01$), which indicates variations in the nuclear function. In this way, the effects observed (cell renewal and hydration) are very important in the products used to prevent and to improve cutaneous aging.

In our studies, both the formulations containing vitamin A palmitate or glycolic acid caused increased epidermal thickness, but these alterations were even more evident with the use of the formulation containing a combination of vitamin A palmitate and glycolic acid. This is probably due to the presence of the glycolic acid in the gel formulation studied, increasing the behavior of skin penetration by vitamin A palmitate and potentiating its effects (20).

Finally, we speculate that AHAs may promote collagen synthesis in human skin (18). It should be remembered that ascorbic acid (an AHA in the lactone form) stimulates procollagen synthesis in fibroblasts in culture (21).

CONCLUSIONS

Under the present experimental conditions, we observed that glycolic acid, combined or not with vitamin A, acts on guinea pig skin by provoking thickening of the epithelium due to an increased cell volume caused by intra- and extracellular edema (hydration). This thickening is not limited to the upper cell layers but is also present in the basal and spinous layers.

REFERENCES

(1) R. Hermitte, Aging skin, retinoids and alpha hydroxy acids, *Cosmet. Toiletr.,* **107**, 63–67 (1992).
(2) W. A. Merz, Die streckenmessung und gerichteten strukfuren im mikroskop und ihre anwendung zur bestimmung von oberflächen—volumen relationen im knochengewebe, *Mikroskopie,* **22**, 132–142 (1968).
(3) M. Delesse, Procédé mécanique pour déterminer la compasiton des roces, *Annales de Mines,* **13**, 379–388 (1847).
(4) H. W. Chalkley, Method for the quantitative morphologic analysis of tissues, *J. Nat. Cancer Inst.,* **4**, 47–53 (1943).
(5) E. R. Weibel, Principles and methods for the morphometric study of the lung and other organs, *Lab. Invest.,* **12**, 131–155 (1963).
(6) A. Hennig, Feher der oberflachenbestimmung von kerner bei endlicher schimittdicke, *Mikroskopie,* **12**, 7–11 (1957).
(7) M. Abercrombie, Stimulations of nuclear populations from microforme sections, *Ant. Rec.,* **94**, 239 (1946).
(8) H. Elias, *et al.,* Some methods for the study of kidneys structures, *Z. Wiss. Mikrosk.,* **5**, 70 (1961).
(9) E. R. Weibel, Principles and methods for the morphometric study of the lung and other organs, *Lab. Invest.,* **12**, 131–155 (1963).
(10) E. Van Scott and R. J. Yu, Hyperkeratinization, corneocyte cohesion and alpha hydroxy acids, *J. Am. Acad. Dermatol.,* **11**, 867–879 (1984).
(11) W. P. Smith, Hydroxy acids and skin aging, *Cosmet. Toiletr.,* **109**, 41–44 (1994).
(12) E. Van Scott and R. J. Yu, "Substances That Modify the Stratum Corneum by Modulating Its Formation," in *Principles of Cosmetics for the Dermatologist,* P. Frost and S.N. Horwitz, Eds. (Mosby, St. Louis, 1982), pp. 70–74.
(13) M. Rieger, Ceramides: Their promise in skin care, **111**, 33–45 (1996).
(14) B. Idson, Dry skin: Moisturizing and emolliency, *Cosmet. Toiletr.,* **107**, 69 (1992).
(15) R. M. Lavker, *et al.,* Effects of topical ammonium lactate on cutaneous atrophy from a potent corticosteroid, *J. Am. Acad. Dermatol.,* **26**, 535–544 (1992).
(16) H. Pinkus, Examination of the epidermis by strip method, *J. Invest. Dematol.,* **19**, 431–447 (1952).
(17) P. Zheng, *et al.,* Morphologic investigations on the rebound phenomenon after corticoid-induced atrophy in human skin, *J. Invest. Dermatol.,* **82**, 345–352 (1984).
(18) P. M. Elias and M. L. Williams, Retinoids, cancer and the skin, *Arch. Dermatol.,* **117**, 160–180 (1981).
(19) E. Van Scott and R. J. Yu, Alpha hydroxy acids: Procedures for use in clinical practice, *Cutis,* **43**, 222–228 (1989).
(20) G. R. Leonardi and P. M. B. G. Maia Campos, Influence of glycolic acid as a component of different formulations on skin penetration by vitamin A palmitate, *J. Cosmet. Sci.,* **49**, 23–32 (1998).
(21) S. R. Pinnell, *et al.* Induction of collagen synthesis by ascorbic acid: A possible mechanism, *Arch. Dermatol.,* **123**, 1684–1686 (1987).